

Pan-London MTC guidance for patients with REBOA in situ

Introduction

REBOA (resuscitative endovascular balloon occlusion of the aorta) is currently being performed by London's air ambulance for exsanguinating non-compressible haemorrhage. Given the extremely shocked state of these patients they are likely to present to any of the London MTCs and require rapid definitive haemorrhage control and balloon deflation. A working knowledge of REBOA is required and the hospital system prepared to ensure safe, smooth and rapid transition from pre-hospital to definitive care.

REBOA is a bridge to definitive haemorrhage control and should be seen as an emergency procedure to perfuse central organs and ward off cardiac arrest. It carries numerous significant risks, most notably ischaemia to the limbs, bowel, kidneys and spinal cord depending on the level of occlusion.

This summary includes:

1. Background
2. Response to balloon
3. Balloon deflation and removal
4. Post procedure management
5. Appendices: checklist, ED action care, team member roles and patient destination

1. Background

Non-compressible torso haemorrhage is the leading cause of preventable trauma deaths. Trauma systems have optimised access to definitive means of haemorrhage control, however a significant proportion of deaths occur before definitive haemorrhage control can be achieved. Half of shocked patients with a pelvic fracture or a torso vascular injury who ultimately die, suffer a cardiac arrest prior to, or soon after arrival in the Emergency department, before any opportunity for intervention (1).

Currently, resuscitative thoracotomy with aortic compression is the only means of temporary haemorrhage control in catastrophic torso haemorrhage. This procedure is effective in patients with a thoracic source of haemorrhage that can be directly controlled, but is maximally invasive and has poor outcomes in those with sub-diaphragmatic haemorrhage. For a meaningful reduction in mortality from these injuries, novel methods of early haemorrhage control are required.

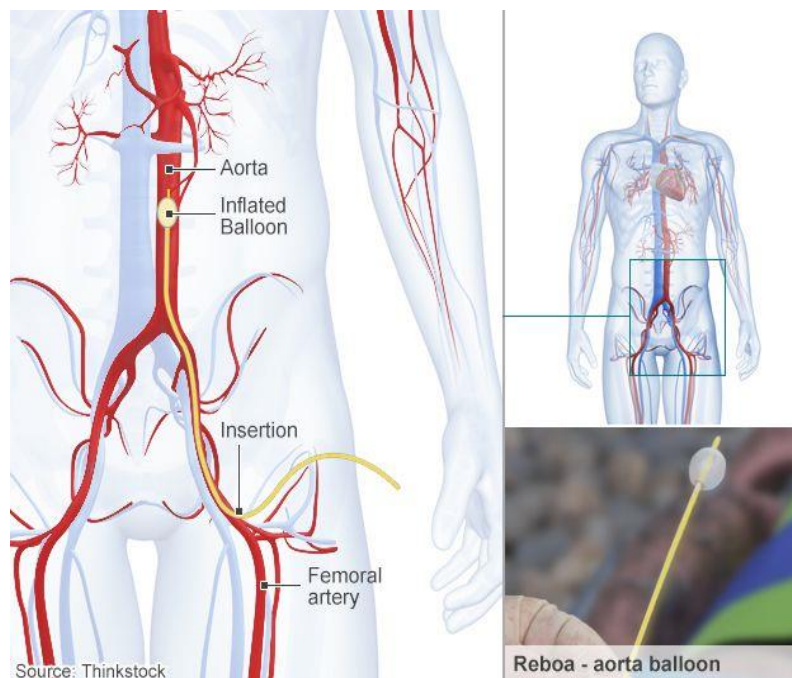
REBOA involves positioning an endovascular balloon in the proximal or distal aorta as a means of inflow control and afterload augmentation in patients with severe non-compressible haemorrhage, providing temporary circulatory support until haemostasis can be achieved (11-14). REBOA carries numerous potential risks, including renal, splanchnic and spinal cord ischaemia and vascular injury.

It should be seen as an extreme temporizing measure to save the life of an exsanguinating patient and to avoid thoracotomy.

Practically speaking, only two areas of the aorta are of interest in the context of catastrophic haemorrhage control: the supra-coeliac aorta (immediately above the coeliac trunk and diaphragm) and the terminal aorta (below the renal and mesenteric arteries). As with an aortic cross clamp, the higher the occlusion, the greater the risk of organ and life-threatening ischaemia.

Procedure summary:

Using a seldinger technique, a 7 French vascular sheath is inserted into the femoral artery and through this a balloon catheter is fed into the aorta. The balloon is inflated to occlude the aorta, reducing blood loss and increasing central perfusion. Current practice is to occlude the terminal aorta at its bifurcation to treat pelvic and junctional vascular (groin) haemorrhage. There may be a move in the future to occlude the supra-coeliac aorta (above the diaphragm) to treat abdominal haemorrhage. It should be noted that, until this is the case, this procedure will not control haemorrhage above the pelvis.



2. Response to balloon:

In the majority, when the balloon is correctly sited, there will be an immediate physiological response including a rise in BP, ETCO₂ and improvement in skin color. However, this may not be 'text book', particularly in a patient who is profoundly hypovolaemic. Such patients may show an initial response followed by a deterioration and they often require aggressive blood product resuscitation as well as immediate transfer to definitive care.

A 'non-textbook' response may be confusing to the clinical team who must decide whether this is due to balloon failure, misplacement, misdiagnosis or simply a successful procedure in a profoundly hypovolaemic patient. This will in turn rely on confidence in the initial diagnosis and confidence in the procedure.

If a patient continues to deteriorate rapidly the clinician must decide whether to deflate the balloon, change position or proceed to laparotomy/thoracotomy. All will depend on the individual patient and surrounding factors, but it is well worth pre-thinking these eventualities.

Conversely, a 'text-book' response with marked improvement in haemodynamics must not distract the team from the urgency of the situation and importance of a short balloon time.

Team leadership

In our experience the team leader must put in a great deal of effort to expedite definitive haemorrhage control and avoid unnecessary interventions and investigations unless absolutely essential.

The team are likely to become distracted given the novel nature of the procedure. It is essential that the team has a leader who is not task focused and that concurrent activity continues. It is our practice that the team leader is not the person performing the procedure or managing the balloon.

Post procedure

Although haemodynamics may improve dramatically following aortic occlusion, balloon inflation time correlates inversely with survival (12), therefore any delays to definitive haemorrhage control must be avoided.

After REBOA, the patient must be transferred to the operating theatre or IR suite as quickly as possible. **Rapid progress to definitive haemorrhage control and balloon deflation is vital.**

CT: Only if there is a well-defined question requires answering urgently (e.g. if you have evidence of an aortic injury or a life threatening intracranial bleed which may require simultaneous surgery), consider CT but remain mindful of

time. Aggressive haemostatic volume resuscitation is required if an attempt at balloon deflation in the CT scanner is to be enabled, both to facilitate a contrast CT scan and to minimise continuous balloon inflation time.

If there is debate about the injury pattern or stability of the patient and whether or not REBOA was required be mindful that the balloon may give the appearance of 'stability' in the face of extreme shock. Trust the judgment of the initial treating team. Consider very carefully before deflating the balloon and undertaking CT, if you do not have the confidence to deflate the balloon, do not delay for a CT which is not absolutely essential.

Decision making

The overriding aim should be definitive vascular control and balloon deflation, these should both be seen as an extreme emergency.

Imaging

As part of the immediate primary survey in the ED resus room, a Chest X-Ray, Pelvic X-ray and FAST scan are likely to yield important information. These patients should not go 'straight to CT' on arrival as this is not indicated in the vast majority and will serve to prolong occlusion time and increase mortality.

If the handover, response to balloon and primary survey reveals a definite indication for CT imaging it may be considered, as described above. Be acutely mindful of time and verbalise a 'plan B' with the whole team.

Interventions

Filling: All patients are likely to need aggressive blood product resuscitation, do not be falsely reassured by an improvement in haemodynamics. In some cases volume resuscitation may need to be limited if blood pressures are supra-normal, but be ready with large bore central access to fill rapidly once the balloon is deflated.

Drugs: Calcium chloride and sodium bicarbonate are likely to help mitigate complications of aortic occlusion and reperfusion as well massive haemorrhage and transfusion. Close dialogue between team leader and senior anaesthetist is essential before and during deflation, the situation can be compared to an aortic cross-clamp.

Time and team management: This should be constantly borne in mind and best practice is to have a separate team leader from the REBOA operator. Be aware of the likely distraction by this novel procedure. Consider very carefully the need for *any* test or intervention which delays time to vascular control and balloon deflation.

Destination

There are a limited number of outcomes following balloon occlusion of the aorta and they will guide your destination:

- **Successful placement and a positive haemodynamic response.**
 - *Push immediately to theatre or interventional radiology*, depending on predicted injury and preparedness of each. See examples in appendix 1.
- **No positive response to balloon occlusion.** One, or all of the sites of haemorrhage may be above the balloon, there has been a complication in the procedure or the balloon is incorrectly placed.
 - *Push immediately to theatre* as there are likely too many unknowns to commit to IR (prolonged time to control and likely multiple bleeding sources). Look carefully for signs of improvement, such as pinkness of the lips, change in ETCO₂, strength of pulses before deciding there is a complication or misdiagnosis, the balloon may be doing it's job but the patient extremely under-filled.
- **Catastrophic deterioration after balloon occlusion.**
 - *Consider balloon deflation if any possibility of complication*, especially IVC placement. Check balloon has not been accidentally deflated/displaced.
 - *Consider emergency thoracotomy* if deteriorating uncontrollably, the bleed may be above the balloon.
- **Damage/complications:** If an iatrogenic injury is suspected and time/stability allows, consider IR as a place to search for and repair the problem. Deflate the balloon if absolutely necessary but leave the wire, catheter and sheath in place.

3. Balloon deflation and sheath removal

- Treat the REBOA balloon as an aortic clamp. Ongoing requirement for REBOA is assessed frequently and balloon inflation time is kept to an absolute minimum. Prolonged balloon inflation is likely to lead to vital organ damage, permanent disability and death. The risks of aortic occlusion must be balanced carefully against the risk of death from uncontrolled haemorrhage.
- The REBOA operator should task a team member with alerting the team every 10 minutes after balloon inflation.

There should be clear indications for balloon deflation:

- First and foremost is when vascular control is obtained by other means, deflation should occur as soon as possible. Deflation may be required in order to confirm haemorrhage control e.g. during laparotomy.

- Balloon deflation may be required in order to gain arterial access in the IR suite. Be prepared to re-inflate quickly if cardiovascular collapse occurs.
- Deflation may be considered during CT if a scan has been deemed essential, both to facilitate a contrast CT scan and to minimise continuous balloon inflation time.

Definitive deflation:

As soon as definitive vascular control is achieved, you should aim to definitively deflate and remove the REBOA catheter. This still requires caution and may precipitate cardiovascular collapse due to loss of afterload, ischaemia and re-perfusion.

Ultimate responsibility for ensuring prompt balloon deflation rests with the trauma team leader coordinating the perioperative phase of the patient's treatment.

- A full resuscitation/theatre team should be present and the balloon deflated in a planned, coordinated manner, following a full team briefing.
- Profound haemodynamic instability is common following balloon deflation due to sudden afterload reduction, hypovolaemia, reperfusion of ischaemic tissue, washout of metabolic by-products, hyperkalaemia, hypocalcaemia and acidosis.
- Sodium Bicarbonate and Calcium Chloride may help to reduce these metabolic effects and close discussion with the anaesthetist in charge is vital.
- Blood products should be immediately available, for administration through an appropriate warming device and these sequelae prepared for.
- On deflation, if severe haemodynamic instability is precipitated, a period of intermittent balloon inflation and titrated deflation may be required. At this stage, care must be taken to prevent distal migration of the balloon as described above.
- Once REBOA is no longer deemed necessary, the REBOA operator may withdraw the balloon catheter. The sheath should be flushed with saline and the IABP monitoring line connected to the side arm of the 7Fr sheath. Sheath removal will require input from the vascular surgeon or interventional radiologist, including closure of the vessel wall defect and active exploration for thrombus.

4. Post Procedure

Thrombus: Arterial thrombus is very likely, even in the coagulopathic patient, and clot should be actively sought *in every case* to avoid compounding the effects of balloon occlusion with devastating consequences.

Re-vascularisation should be achieved urgently and very close attention paid to limb perfusion and compartment pressures over the coming days.

As with an aortic cross clamp there is a risk of a reperfusion insult, rhabdomyolysis and vital organ dysfunction. The patient should remain closely monitored in a high dependency area following the procedure.

HEMS Data collection:

Accurate and complete data collection is essential. The task of data sheet completion should be the responsibility of the HEMS REBOA operator who performed the procedure. If any missing data or completed data collection forms remain in your MTC, please return to Dr Samy Sadek, ED Consultant at the Royal London Hospital, (samy.sadek@bartshealth.nhs.uk) and Frank Chege, Patient Liaison Nurse at London's Air Ambulance (f.chege@londonsairambulance.co.uk).

Appendix 1: Emergency Department preparation checklist.

ED REBOA CHECKLIST	
Pre-alert:	
- Establish whether REBOA performed, which zone and timing	
Activate:	
- Massive haemorrhage protocol	
- Full Trauma Team Response	
- Ensure key team members informed and present or prepared:	
○ Consultant and senior nurse in ED	
○ Vascular + Trauma surgery	
○ Interventional Radiology	
○ Anaesthesia	
○ ITU	
○ 'REBOA operator'	
Prepare:	
- Resus bay	
- Trauma team – action cards distributed	
- Blood products ready to give warmed	
- Drugs: CaCl, NaBicarb, TXA, Anaesthetic	
- Equipment: thoracotomy pack, trauma line	
- Portable X ray ready	
- Ultrasound scanner ready	
- Emergency theatre open	
- Interventional radiology suite open	
- Route to theatre/IR clear	

Appendix 2: Emergency Department actions.

Emergency Department ACTION CARD

On arrival in the ED, the key priorities are:

- **Establish pattern of injury**
- **Establish response to balloon**
- **Make rapid clinical diagnosis**
- **Push to definitive control**
- **Minimize balloon time**

Imaging:

- CXR, PXR and FAST are useful
- CT adds time and carries high risk: *only consider if a specific urgent question requires answering*

In theatre:

- Control haemorrhage urgently
- Visualise/feel balloon position in aorta
- Deflate balloon ASAP when haemorrhage controlled
- If haemorrhage recurs, re-inflate balloon and control surgically
- *Brief entire team before deflation*
- Ensure balloon catheter does not migrate when deflated

In IR:

- Consider balloon catheter removal or access to contralateral side
- Likely need deflation to visualize and access vessels
- Rescue/repair of any complications,

After definitive deflation:

- Remove central balloon catheter, *with guidewire*
- Note total balloon occlusion time
- Leave arterial sheath in place until formal removal and vascular repair
- Sheath has a self sealing port, side port may be used as arterial transducer
- Complete data collection sheet

Post procedure:

- Consider full CT imaging depending on progress and clinical state
- Thrombus: ***actively seek in all cases***
- Formal vessel closure as required with sheath removal
- Watch carefully for limb thrombus, ischaemia and compartment syndrome

Appendix 3: Recommended individual roles.

Individual team member Action Cards:

To be developed by the MTCs, depending on individual systems, but to contain the following team members and these basic principles:

Trauma team leader

Role – decision making and situational awareness

Senior ED nurse

Role – coordinate monitoring, blood transfusion and equipment

Trauma surgery consultant

Role – decision on definitive care

Senior anaesthetist

Role – orchestrate resuscitation and anaesthesia

ODP

Role – ensure safe anaesthesia and expedite transfer

Interventional Radiologist

Role – definitive haemorrhage control +/- rescue or repair from procedure

Theatre coordinator

Role – ensure swift transfer to and through theatres

REBOA Operator

Role – ‘manage’ the balloon catheter

- Ensure balloon is not displaced during movement
- Monitor balloon time and alert the team every 10 minutes
- Stay with patient until balloon deflated
- Ensure data collection completed

Appendix 4: Destination

The immediate 'destination' for a patient after arrival in hospital is crucial. In order to aid decision making and avoid delays it is worth pre-thinking the likely situations, in the context of your MTC's process and resources.

These are not fixed or exclusive and depend on individual circumstances, hence examples are given but an algorithm is not drawn.

Theatre or IR?

- FAST negative with a pelvic fracture: IR if ready immediately, if not, to theatre for damage control surgery.
- FAST positive with a pelvic fracture: IR if ready immediately and you are certain the pelvis is the source of bleeding, if not, to theatre damage control surgery.
- Stab wound to groin: to theatre for damage control surgery.
- Stab wound to buttock: Consider IR if ready and you are certain the pelvis is the source of bleeding, if not, to theatre damage control surgery.

Need for an immediate CT?

As mentioned, only if a well-defined question requires answering *urgently* consider CT but remain mindful of time.

- Evidence of a skull fracture but high GCS on scene, or normal pupils at primary survey.
- Possibility of aortic injury but no hard signs.
- Concern re the exact pattern of injury and other associated injuries.

Do not scan now, push to IR or theatre. CT should be delayed until the primary life-threatening problem is treated and the balloon is deflated. Apparent 'haemodynamic stability' is created by the balloon and ischaemic time is building. Ensure team leader is aware that CT is required as soon as possible after haemorrhage control is achieved and balloon deflated.

- Strong signs of a life threatening intracranial bleed with mass effect and neurosurgeons able to operate simultaneously with damage control surgery: consider immediate CT.
- Strong evidence of aortic injury and the means to repair this concurrently are available: consider immediate CT.

Think carefully about what you are scanning and why, consider deflating balloon for CT depending on injuries and response, verbalise your 'plan B' should the patient deteriorate or scanning become prolonged.

References

1. Perkins ZB, De'Ath HD, Aylwin C, Brohi K, Walsh M, Tai NRM. Epidemiology and outcome of vascular trauma at a British Major Trauma Centre. *Eur J Vasc Endovasc Surg.* 2012 Aug.;44(2):203–9.
2. Veith FJ, Lachat M, Mayer D, Malina M, Holst J, Mehta M, et al. Collected world and single center experience with endovascular treatment of ruptured abdominal aortic aneurysms. *Ann Surg.* 2009 Nov.;250(5):818–24.
3. Karkos CD, Harkin DW, Giannakou A, Gerassimidis TS. Mortality after endovascular repair of ruptured abdominal aortic aneurysms: a systematic review and meta-analysis. *Arch Surg.* 2009 Aug.;144(8):770–8.
4. Malina M, Veith F, Ivancev K, Sonesson B. Balloon occlusion of the aorta during endovascular repair of ruptured abdominal aortic aneurysm. *J. Endovasc. Ther.* 2005 Oct.;12(5):556–9.
5. Karkos CD, Bruce IA, Lambert ME. Use of the intra-aortic balloon pump to stop gastrointestinal bleeding. *Ann Emerg Med.* 2001 Sep.;38(3):328–31.
6. Harma M, Harma M, Kunt AS, Andac MH, Demir N. Balloon occlusion of the descending aorta in the treatment of severe post-partum haemorrhage. *Aust N Z J Obstet Gynaecol.* 2004 Apr.;44(2):170–1.
7. Gupta BK, Khaneja SC, Flores L, Eastlick L, Longmore W, Shaftan GW. The role of intra-aortic balloon occlusion in penetrating abdominal trauma. *The Journal of Trauma: Injury, Infection, and Critical Care.* 1989;29:861–5.
8. White JM, Cannon JW, Stannard A, Markov NP, Spencer JR, Rasmussen TE. Endovascular balloon occlusion of the aorta is superior to resuscitative thoracotomy with aortic clamping in a porcine model of hemorrhagic shock. *Surgery.* 2011 Sep.;150(3):400–9.
9. Morrison JJ, Percival TJ, Markov NP, Villamaria C, Scott DJ, Saches KA, et al. Aortic balloon occlusion is effective in controlling pelvic hemorrhage. *J Surg Res.* 2012 Oct.;177(2):341–7.
10. Moore LJ, Brenner M, Kozar RA, Pasley J, Wade CE, Baraniuk MS, et al. Implementation of resuscitative endovascular balloon occlusion of the aorta as an alternative to resuscitative thoracotomy for noncompressible truncal hemorrhage. *The Journal of Trauma and Acute Care Surgery.* 2015 Oct.;79(4):523–32.
11. Stannard A, Eliason JL, Rasmussen TE. Resuscitative endovascular balloon occlusion of the aorta (REBOA) as an adjunct for hemorrhagic shock. *The Journal of Trauma: Injury, Infection, and Critical Care.* 2011 Dec. 1;71(6):1869–72.

12. Martinelli T, Thony F, Decléty P, Sengel C, Broux C, Tonetti J, et al. Intra-aortic balloon occlusion to salvage patients with life-threatening hemorrhagic shocks from pelvic fractures. *J Trauma*. 2010 Apr.;68(4):942–8.
13. Brenner ML, Moore LJ, DuBose JJ, Tyson GH, McNutt MK, Albarado RP, et al. A clinical series of resuscitative endovascular balloon occlusion of the aorta for hemorrhage control and resuscitation. *Journal of Trauma and Acute Care Surgery*. 2013 Sep. 1;75(3):506–11.
14. Ogura T, Lefor AT, Nakano M, Izawa Y, Morita H. Nonoperative management of hemodynamically unstable abdominal trauma patients with angioembolization and resuscitative endovascular balloon occlusion of the aorta. *The Journal of Trauma and Acute Care Surgery*. 2015 Jan.;78(1):132–5.